

# Influence of Implant Structure on Interbody Fusion: Porous Nitinol vs. Titanium Implants

Likibi, F<sup>1</sup>, Assad, M<sup>2</sup>, Chabot, G<sup>1</sup>, Leroux, MA<sup>2</sup>, Rivard, C-H<sup>1</sup>

<sup>1</sup> Ste-Justine Hospital, Paediatric Research Center, Montreal, QC, Canada

<sup>2</sup> Biorthex Inc., Department of Research and Development, Montreal, QC, Canada

## Introduction:

Bone represents a tissue in constant remodeling. Following surgical trauma or presence of foreign bodies for example, bone defense mechanisms have either a temporary or definitive impact on bone remodeling. In turn, any change in the bone formation/resorption couple will lead to important consequences such as the loss of bone structure integrity [1]. In this study, two types of metallic intervertebral fusion implants were evaluated for bone fusion and structural change in the peripheral tissue mass after 3, 6 and 12 months post-implantation in sheep.

## Materials and methods:

**Surgical technique:** Mature female sheep underwent 2 level interbody surgery (L2-L3 and L4-L5) with one porous nitinol (PNT) implant ( $\phi 11 \times 20$ mm,  $230 \pm 130 \mu\text{m}$  pores,  $65 \pm 5\%$  porosity; Actipore™, Biorthex Inc.) and one hollow TiAlV fusion cage ( $\phi 11 \times 20$ mm; BAK™, Sulzer Spine-Tech Inc.). The TiAlV cage was filled with iliac crest bone. Then, both implants were positioned using posterior lumbar interbody fusion (PLIF) instrumentation.

**Tissue harvest:** Sheep were sacrificed after 3, 6 and 12 months post-surgery (4-6 sheep/time point). Lumbar units were removed, placed in neutral formalin (10%), and prepared for ground sectioning. Lumbar segments were sectioned at 5mm increments. Specimens were dehydrated in ethanol, cleared with xylene, then embedded in PMME for 3 weeks. Sections were ground to  $60 \mu\text{m}$  and stained with Stevenel's blue and van Gieson's picrofuchsin [2,3].

**Histological analysis:** Slides were evaluated under a digital camera (Nikon Model E 950). Direct contact of sole bone matrix to the implant was the criterion chosen for complete bone fusion. Incomplete fusion was represented by a mix of both hard and soft tissue at the implant periphery. Absence of bone fusion was designated by the sole presence of soft tissue peripheral to the implant. Structural change at implant periphery was evaluated under light microscopy (Leica DM LP,  $\times 400$ ).

**Statistical analysis:** Univariate analyses using  $\chi^2$  and Fisher exact tests were performed on implant types.

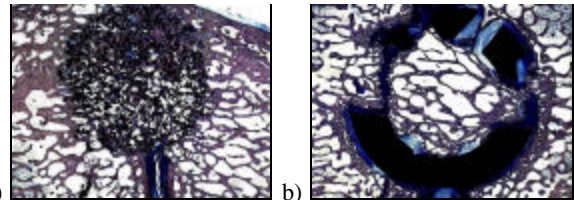
## Results:

PNT samples (15/16, 93.75%, Table 1) demonstrated bone integration and apposition (Fig. 1), whereas only 4/16 TiAlV implants (25.0%, Table 1) offered complete bone fusion. PNT bone bridging at 3 and 6 months was significantly superior compared to TiAlV materials ( $p=0.05$ , Table 1). Peripheral to the PNT implant, a microscopic analysis revealed the presence of either osteoblasts or soft tissue fibers, which were oriented perpendicularly to the surface (3 months, Fig. 2a). Osteoblasts were observed to actively synthesize bone matrix. TiAlV materials were surrounded by soft tissue, chondrocytes, and osteoclasts. Fibrous tissue fibers showed a parallel disposition to the TiAlV surface at 3 months (Fig. 2b), with their orientation slowly evolving to a perpendicular one at 6 and 12 months (Fig. 2c and d, respectively) leading to an effective osseointegration.


**Table 1.** Implant bone fusion over post-surgery time.

	3 months	6 months	12 months	Total
PNT*	5/6	6/6	4/4	15/16
TiAlV	1/6	0/6	3/4	4/16

\*Statistically different from TiAlV at 3 and 6 months post-surgery ( $p=0.05$ , Fisher exact).



**Fig. 1.** PNT (a) and TiAlV (b) implants after 12 months.



**Fig. 2.** Soft tissue fiber orientation in presence of PNT at 3 months (a) and TiAlV implants at either 3 (b), 6 (c) and 12 months (d). [Arrows and plain lines designate implant surface and fiber orientation, respectively].

## Discussion:

Bone matrix formation was obtained in presence of PNT implants due to important osteoblastic activity necessary for osteoid formation (Fig. 1a), whereas bone resorption and endochondral calcification were observed peripheral to TiAlV implants (Fig. 1b). It is possibly the result of a lack of biofunctionality, since TiAlV cages do not possess microporosity features. In turn, it is hypothesized that soft tissue influences bone integration: bone progenitor cells may migrate following fiber orientation. Indeed, as opposed to a parallel disposition of fibers (TiAlV, 3 months, Fig. 2b), osseointegration tends to be favored when fibrous tissue is perpendicular to the implant (PNT, 3 months, Fig. 2a.; TiAlV, 12 months, Fig. 2d). Whereas non-porous materials favored parallel orientation, PNT therefore initiated a perpendicular disposition of soft tissue fibers, which was followed by bone matrix secretion in order to achieve osseointegration.

## References:

- [1] Karsenty G. *Genes Dev* 1999;13(23):3037-3051.
- [2] Meraw S.J. *et al. J Periodontol* 1999;70(2):151-158.
- [3] Froum S. *et al. J Periodontol* 2002;73(1):94-102.