

# Computer Tomography Evaluation of Periprosthetic Bone Density Following Intebody Fusion

Likibi, F<sup>1</sup>, Assad, M<sup>2</sup>, Chabot, G<sup>1</sup>, Leroux, MA<sup>2</sup>, Rivard, C-H<sup>1</sup>

<sup>1</sup> Ste-Justine Hospital, Paediatric Research Center, Montreal, QC, Canada

<sup>2</sup> Biorthex Inc., Department of Research and Development, Montreal, QC, Canada

## Introduction:

Interbody fusion is the most widely used technique to treat degenerative disc pathologies. Intervertebral cages must produce a durable biological and mineralized link in order to achieve bone bridging. In presence of a biocompatible implant, an intimate bone-implant relationship develops, promoting bone tissue ingrowth and achieving an effective intervertebral fusion. Once the fusion is obtained, mobility between the bone-implant couple is reduced. The stability of the bone-implant interface will in turn have an effect on the extent of the surrounding callous and sclerosis formation. In this study, two intervertebral implants were evaluated for their fusion capacity using computer tomography (CT) in order to measure surrounding bone density (BD) and evaluate bone remodeling properties.

## Materials and methods:

**Experimental design and surgical technique:** Mature female sheep (1-2 years old) underwent 2-level interbody surgery (L2-L3 and L4-L5) with one ungrafted porous nitinol (PNT) implant ( $\phi 1 \times 20$ mm,  $230 \pm 130 \mu\text{m}$  pores,  $65 \pm 5\%$  porosity; Actipore™, Biorthex Inc.) and one hollow threaded TiAlV fusion cage ( $\phi 1 \times 20$ mm; BAK™, Sulzer Spine-Tech Inc.). The TiAlV cage was filled with iliac crest bone chips, then screwed into position using a posterior lumbar interbody fusion (PLIF) instrumentation.

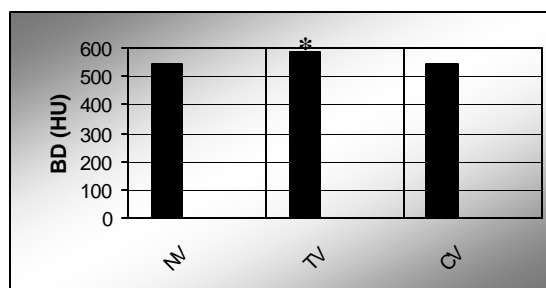
**CT bone density evaluation:** To evaluate the progression of BD with time, sheep were sacrificed after 3, 6 and 12 months post-surgery (4-6 sheep/time point). One untreated control sheep was sacrificed at each period. Following the implantation period, spinal columns were removed as units (L1-L6) and placed under a PQ 5000 CT scan (4<sup>th</sup> helicoidal generation with spiral acquisition; Philips Medical Systems). Using three vertebral slices (2-mm thick and 2mm between slices), implant images were acquired by measuring the average density at the centre of the vertebral slice (120mm, 130KV, 30mA, 1s; Resolution: 512x512 pixels). Results were compared to vertebrae from untreated control sheep and then stratified according to material type and implantation time.

**Statistical analysis:** The Student's t-test was used to determine if any statistical difference existed between implant-adjacent and untreated vertebrae BDs.

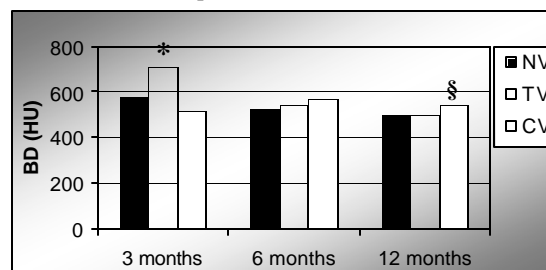
## Results

Average bone densities surrounding intervertebral implants were first evaluated regardless of post-surgical implantation time (Fig. 1). Density change in vertebrae adjacent to PNT (NV) and TiAlV (TV) implants was compared to that of untreated controls (CV). The difference in density observed with PNT-treated and untreated vertebrae was not statistically different (NV=540HU and CV=544HU). Therefore, BD adjacent to porous nitinol did not seem to increase from physiological values. In presence of titanium cages, a significant BD increase was however observed. Indeed, the density difference between TiAlV-treated and untreated sheep was significant (TV=582HU and CV=544HU,  $p=0.01$ ).

Implantation time also seemed to have an impact on bone density (Fig. 2). After a 3-month implantation period, TiAlV-treated animals obtained significantly higher periprosthetic BD values when compared to both PNT-treated and untreated animals ( $p=0.01$ ). At 6 months, there were no significant BD differences between treated and untreated vertebrae. After 12 months of instrumentation, bone density measured with both PNT and TiAlV implants had significantly decreased compared to control values (NV vs. CV,  $p=0.01$ ; TV vs. CV,  $p=0.05$ ).



**Figure 1.** Vertebral BD in presence of PNT and TiAlV implants vs. untreated control vertebrae. [\*Statistically different from CV ( $p=0.05$ , Student's t-test)].



**Figure 2.** Vertebral BD variation over time. [\*Statistically different from NV and CV; §Statistically different from NV and TV ( $p=0.05$ , Student's t-test)].

## Discussion:

Periprosthetic BD surrounding PNT implants was found to be generally inferior to that of TiAlV cages. However, it was not significantly different than the general BD found in untreated control vertebrae, indicating an adequate bone remodeling through time. Callous formation in presence of PNT is the result of normal bone healing. Compared to control vertebrae, a significantly higher BD surrounding TiAlV cages was indicative of an osteosclerosis phenomenon in response to the potential instability at the bone-implant interface. Regardless of material type, BD decrease at 12 months is a normal consequence to traumatic ischemia. Normal BD is expected to be restored once the vascular network is completely re-established. The good performance of porous nitinol is linked to its biofunctionality and microporous structure [1,2].

## References:

- [1] Steflik D.E. *et al.* Adv Dent Res 1999;13:27-33.
- [2] Tamai N. *et al.* JBMR 2002;59(1):110-117.