

# EFFECT OF IMPLANT STRUCTURE ON BONE APPosition AND INTEGRATION: COMPARATIVE STUDY OF TWO POSTERIOR LUMBAR FUSION DEVICES

\*Likibi, F; \*Chabot, G; +\*\*Assad, M; \*Coillard, C; \*\*Leroux, M A; \*Rivard, C-H

\*Ste-Justine Hospital, Paediatric Research Center, Montreal (QC) Canada. +\*\*Biorthex Inc., R&D Dept., Montreal (QC) Canada

## INTRODUCTION:

Bone represents a tissue in constant remodeling. Osteoclasts are known to catabolise bone matrix, while osteoblasts secrete new bone matrix directly apposed to the original one. Following surgical trauma or presence of foreign bodies for example, bone defense mechanisms have either a temporary or definitive impact on bone remodeling. In turn, any change in the formation/resorption couple will lead to important consequences such as the loss of bone structure integrity for example [1]. In this study, two types of metallic intervertebral lumbar fusion implants were studied in a lumbar sheep model in order to evaluate bone bridging, osseointegration, and structural change induced in the peripheral tissue mass after 3, 6 and 12 months post-implantation.

## MATERIALS AND METHODS:

### Experimental design and surgical technique:

Mature female sheep (1-2 years old) simultaneously underwent 2 level interbody surgeries (retroperitoneal approach; left lumbar regions L2-L3 and L4-L5) with one ungrafted porous nitinol (PNT) implant ( $\phi 11 \times 20\text{mm}$ ,  $230 \pm 130\mu\text{m}$  pores, 65±5% porosity; Actipore™, Biorthex Inc., Montreal, QC, Canada) and one hollow threaded TiAIV fusion cage ( $\phi 11 \times 20\text{mm}$ ; BAK™, Sulzer Spine-Tech Inc., Minneapolis, MN, USA). The TiAIV cage was first filled with iliac crest bone chips, then screwed into position using a slightly modified posterior lumbar interbody fusion (PLIF) instrumentation. The PNT implant was inserted in the second intervertebral space in absence of autograft seeding. The wound was closed in layers and sheep were allowed to recover for 3, 6, and 12 months following interbody surgery (4-6 sheep/time point). Animal care complied with the Canadian Council on Animal Care (CCAC) guidelines for care and use of experimental animals.

### Evaluation protocol:

**Necropsy and tissue harvest:** Spinal columns were removed as units (L1-L6), placed in neutral formalin (10%), and prepared for ground sectioning. After fixation, L2-L3 and L4-L5 segments were isolated. Implants were sectioned at increments of 5mm. Following trimming, specimens were dehydrated in ethanol and cleared with xylene. Undecalcified tissues were then embedded in methylmethacrylate for 3 weeks. 100 to 300- $\mu\text{m}$  sections were taken using an EXAKT saw and ground to 60 $\mu\text{m}$ . Each section was then stained with Stevenel's blue (soft tissue) and van Gieson's picrofuchsin (bone tissue) [2,3].

**Macroscopic analysis:** A thorough macroscopic analysis was performed on histological slides using a digital camera (Nikon Model E 950). Direct contact of sole bone matrix to the implant was the criterion chosen for complete bone fusion. Incomplete fusion was represented by a mix of both hard and soft tissue at the implant periphery. Absence of bone fusion was designated by the sole presence of soft tissue peripheral to the implant.

**Microscopic analysis:** Structural change at implant periphery was evaluated using transmitted light microscopy (Leica DM LP,  $\times 400$ ).

**Statistical analysis:** Univariate analyses using chi-square and Fisher exact tests were performed to determine if any statistically significant difference existed between lumbar implants

## RESULTS:

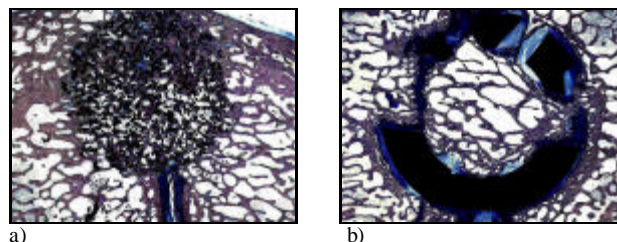
The majority of PNT samples (15/16, 93.75%, Table 1) demonstrated bone integration and apposition, whereas only 4 out of 16 TiAIV implants (25.0%, Table 1) were shown to offer complete bone fusion. PNT bone bridging at 3 and 6 months was significantly superior compared to TiAIV materials ( $p=0.05$ ); the difference was not statistically significant at 12 months (Fig. 1).

Peripheral to the PNT implant, a microscopic analysis revealed the presence of either osteoblasts or soft tissue fibers. The latter were specifically oriented perpendicularly to the surface regardless of implantation time (Fig. 2a). Osteoblasts were observed to actively synthesize bone matrix. The TiAIV materials were surrounded by soft tissue, chondrocytes, and osteoclasts. Fibrous tissue fibers showed a parallel disposition to the TiAIV implant surface at 3 months (Fig. 2b), with their orientation slowly evolving to a perpendicular one starting at 6 months (Fig. 2c) and completing at 12 months post-instrumentation (Fig. 2d) leading to an effective osseointegration.

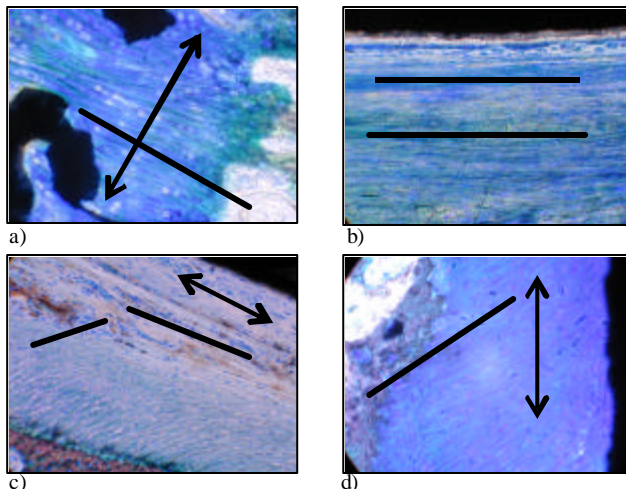
**Table 1.** Implant bone fusion over post-surgery recovery time.

	3 months	6 months	12 months	Total
PNT*	5/6	6/6	4/4	15/16
TiAIV	1/6	0/6	3/4	4/16

\*Statistically different from TiAIV at 3 and 6 months post-surgery ( $p=0.05$ , Fisher exact).



**Figure 1.** PNT (a) and TiAIV (b) implants after 12 months post-implantation.



**Figure 2.** Soft tissue fiber orientation in presence of PNT at 3 months (a) and TiAIV implants at either 3 (b), 6 (c) and 12 months (d) post-instrumentation. [Arrows and plain lines designate implant surface direction and fiber orientation, respectively].

## DISCUSSION:

Bone matrix formation was observed in presence of porous nitinol implants due to important osteoblastic activity necessary for osteoid formation (Fig. 1a). In the case of TiAIV, bone resorption and endochondral calcification were however observed peripheral to the implants (Fig. 1b). It is possibly the result of a lack of biofunctionality, since threaded TiAIV fusion cages do not possess microporosity features. In turn, it is hypothesized that soft tissue influences bone integration: bone progenitor cells may migrate following fiber orientation. Indeed, as opposed to a parallel disposition of fibers (TiAIV, 3-6 months, Fig. 2b-c), osseointegration tends to be favored when fibrous tissue is perpendicular to the implant (PNT, 3-12 months, Fig. 2a; TiAIV, 12 months only, Fig. 2d). Whereas non-porous materials tend to favor parallel orientation, a porous material such as porous nitinol has therefore initiated a perpendicular disposition of soft tissue fibers, which is followed eventually by osteoblast colonization and bone matrix secretion in order to achieve rapid osseointegration.

## REFERENCES:

- [1] Karsenty G. *Genes Dev* 1999;13(23):3037-51.
- [2] Meraw S.J. *et al J Periodontol* 1999;70(2):151-8.
- [3] Froum S. *et al. J Periodontol* 2002;73(1):94-102.