

INTERVERTEBRAL BODY FUSION USING A POROUS NITINOL ALLOY: 1-YEAR STUDY IN A SHEEP LUMBAR SPINAL MODEL

+*Assad, M; **Jarzem, P; *Leroux, M A; ***Coillard, C; ***Rivard, C H
+*Biorthex Inc., R&D Dept., Montreal (QC) Canada

INTRODUCTION:

Intervertebral disc degeneration with consequent chronic low back pain and lumbar dysfunction represents a major affliction within the working population. In particular, cases of internal disc instability, height reduction, herniation, infection and disruption are often observed. Treatment with spinal fusion cages was therefore introduced to provide immediate interbody fixation, mechanical stability, intervertebral fusion, disc height distraction, and consequent pain relief. Some disadvantages of spinal cages using autologous bone grafting were however noticed: long operative time, significant blood loss, graft harvest site morbidity, and high non-union rates. Porous osteogenic materials represent an alternative to traditional cage implants. For example, porous nitinol (PNT) alloys and their interconnected fenestration trigger both fluid and cellular capillarity. Therefore, porous nitinol should promote bone ingrowth, immediate fixation, and eventual intervertebral fusion without the need for bone grafting. The objective of this study was therefore to compare an ungrafted PNT interbody fusion device to a conventional hollow TiAlV fusion cage based on bone ingrowth capacity, fusion success and distractive properties.

MATERIALS AND METHODS:

Experimental design and surgical technique:

Mature female sheep (1-2 years old) simultaneously underwent 2 level interbody surgery (retroperitoneal approach; left lumbar regions L2-L3 and L4-L5) with one ungrafted porous nitinol (PNT) implant ($\phi 1 \times 20$ mm, $230 \pm 130 \mu\text{m}$ pores, 68% porosity; Actipore™, Biorthex Inc., Montreal, QC, Canada) and one hollow threaded TiAlV fusion cage ($\phi 1 \times 20$ mm; BAK™, Sulzer Spine-Tech Inc., Minneapolis, MN, USA). The TiAlV cage was first filled with iliac crest bone chips, then screwed into position using a slightly modified posterior lumbar interbody fusion (PLIF) instrumentation. The PNT implant was inserted in the second intervertebral space in absence of autograft seeding. The wound was closed in layers and the sheep were allowed to recover for 3, 6, and 12 months following interbody surgery (4-6 sheep/time point). Animal care complied with the Canadian Council on Animal Care (CCAC) guidelines for care and use of experimental animals.

Evaluation protocol:

Histomorphometry: The spinal columns were removed as units (L1-L6), placed in neutral formalin (10%), and prepared for ground sectioning. After fixation, L2-L3 and L4-L5 segments were isolated. Implants were then sectioned at increments of 5mm. Following trimming, specimens were dehydrated in ethanol and cleared with xylene. Undecalcified tissues were then embedded in methylmethacrylate for 3 weeks. 100 to 300- μm sections were taken using an EXAKT saw and ground to 60 μm . Each section was then stained with Stevenel's blue and van Gieson's picrofuchsin. All individual 100 \times histological fields, contained within the metal perimeter, were acquired using transmitted light microscopy (Nikon Model Eclipse ME-600D) combined to a color analog camera (Sony DXC-950P; Clemex Image Analysis, Longueuil, QC, Canada) and a 3-axis motorized stage (Model ST100; Clemex Image Analysis). In parallel, a computer program was developed to sequentially acquire bone, soft tissue, and metal respective surfaces using an image analysis software (Clemex Vision™ 3.0; Clemex Image Analysis). For each entire histological slide, mineralized bone matrix ingrowth areas, excluding any trabecular area, was measured as percentage of the total void area [bone%/(100%-metal%)].

Radiological fusion analysis and interbody distraction index: Frontal and lateral x-rays of specimens were evaluated for absence of peripheral halo and presence of bone bridging by 3 surgeons in a blind fashion. A radiological fusion score (RFS) was developed: 12 points (max. 24) was considered fusion success. Pre-op and post-op lateral x-rays were then numerized. An interbody (IB) distraction index was adapted from Sandhu et al. [1] using vertebral body and disc height measurements along the lumbar spine. The IB index was defined as [fusion height - (L1 + L6 height)]/average body height. The post-op IB index was then pressed as a ratio to the pre-op IB index.

RESULTS:

Based on histology assessment (Fig.1), PNT demonstrated a faster endoprosthetic ossification rate than the TiAlV cages (Fig. 2). Indeed, PNT implant bone ingrowth gradually increased from 21.4% to 37.6% (3-12 mo., Fig. 2) and was systematically higher than that of TiAlV (22.8%-25.4%, 3-12 mo.). Moreover at 6 and 12 months, PNT mineralized bone content (MBC) was even higher than basal cancellous bone MBC (28.8%). Based on bone bridging and radiolucency criteria, PNT radiological fusion score (RFS) also increased with time (mean RFS: 12.5-18.5, 3-12 mo.) and was systematically higher than that of TiAlV cages (mean RFS: 2.0-15.0, 3-12 mo.). Regardless of implantation time, 81.25% of PNT implants (13/16) obtained fusion success, as opposed to 25% of TiAlV cages (4/16). Additionally, both implants obtained similar success in distraction from pre-op disc height levels until 6 months post-op: regardless of material type, the post-op IB index was higher than the pre-op level at all times except at 12 months.

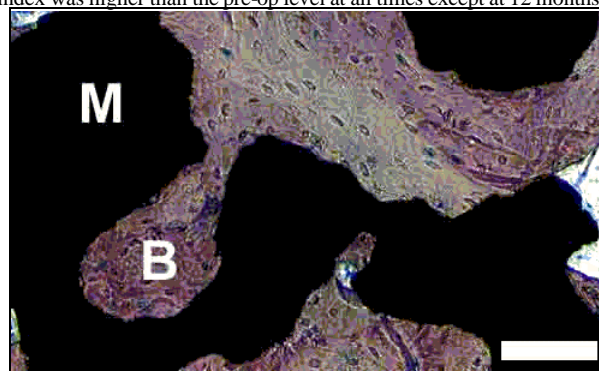


Fig. 1. PTN implant/bone interface after one year of sheep implantation. [Metal (M), mineralized bone matrix (B), bar = 100 μm].

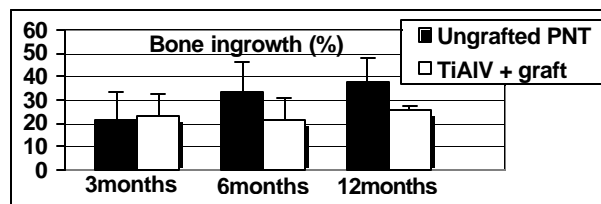


Fig. 2. Mineralized bone content according to implantation time.

DISCUSSION:

Porous nitinol constituted an excellent substrate for woven bone and osteogenic cell integration. PNT bulk structural properties such as high porosity percentage (mean: 68%) and adequate pore size (mean: 230 μm) for capillarity wicking forces, triggered high bone filling percentages reaching up to 37.6% of mineralized bone matrix after one year implantation in sheep. Similarly to bone ingrowth results, PNT radiological fusion scores compared favorably with the non-porous hollow TiAlV control cage currently used for lumbar interbody fusion. Moreover, autologous bone grafting did not confer TiAlV cages any advantage over PNT regardless of implantation time. Therefore, PNT represents a new biomaterial with osteoconductive properties for bone fusion. Potential applications include carrier materials and bone graft substitutes for guided bone regeneration. Soft tissue attachment and repair also represent potential applications of porous nitinol.

REFERENCE:

[1] Sandhu HS et al. Spine 1996;21(10):1201-1210.

ACKNOWLEDGEMENTS:

The authors would like to thank Mrs. S Charette, Dr. K Zabjek, Dr. WJ Kim (Ste-Justine Hospital) and Dr. L Chouinard (CTBR Ltd.; Montreal, QC, Canada) for their excellent technical assistance.

**Santa Cabrini Hospital, Orthopaedics Dept., Montreal (QC) Canada

***Ste-Justine Hospital, Orthopaedics Dept., Montreal (QC) Canada